

Socket Preservation using Acellular Dermal Matrix Allograft in Combination with Xenograft for Dental Implant Placement in Anterior Maxilla: A Case Report

(Pemeliharaan Soket Menggunakan Alocantuman Matriks Dermis Tanpa Sel dalam Gabungan dengan Xenocantum untuk Penempatan Implan Pergigian di Maksila Anterior: Suatu Laporan Kes)

HASLINA TAIB, KHAMIZA ZAINAL ABIDIN, TARA BAI TAIYEB ALI* & NORSIAH YUNUS

ABSTRACT

The collapse of alveolar ridge following tooth extraction is a physiological process which may complicate subsequent implant placement and restoration especially in the aesthetic zone. This case report describes the use of an acellular dermal matrix graft (AlloDerm®, Biohorizon, USA) in combination with bovine bone graft (Bio-Oss®, Geistlich, Switzerland) immediately after tooth extraction for soft and hard tissue augmentation prior to implant placement in the anterior maxilla. The eighth year follow-up demonstrated an acceptable aesthetic outcome indicating that this approach may be employed where tooth extraction is indicated and replacement with implant-supported prosthesis is anticipated particularly in the anterior aesthetic zone region.

Keywords: Bone graft; dental implant; dermal graft; socket preservation

ABSTRAK

Keruntuhan batas alveolus selepas cabutan gigi adalah proses fisiologi yang boleh memberi kesan untuk perletakan implan dan restorasi terutama di zon aestetik. Laporan kes ini menghuraikan penggunaan tisu gantian matriks dermis tanpa sel (AlloDerm®, Biohorizon) digabungkan dengan tulang gantian (Bio-Oss®, Geistlich) di dalam soket sejurus cabutan gigi untuk meninggikan tisu lembut dan tulang sebelum perletakan implan pada bahagian maksila anterior. Penilaian selepas lapan tahun menunjukkan keadaan restorasi yang masih baik, menunjukkan kaedah ini boleh diaplikasikan apabila implan menyokong prostesis dirancang untuk menggantikan gigi yang dicabut terutama di zon estetik.

Kata kunci: Dermis gantian; implan pergigian; pengekal soket; tulang gantian

INTRODUCTION

Alveolar bone resorption which is inevitable following a tooth extraction (Bays 1986; Meccall & Rosenfeld 1991, 1992, 1996) may lead to defects in hard and soft tissues. The deformity of the ridge is directly related to the volume of root structure and associated bone that is missing or has been destroyed. Limited bone volume may lead to less successful restorative treatment outcomes using implants (Lindhe et al. 2003) which originally aimed to restore the aesthetics and function of the natural dentition. This becomes even more challenging in cases of advanced bone loss as a result of trauma, dento-alveolar infection, congenital defects or advanced periodontitis.

Several surgical options for prevention of ridge collapse following tooth extractions have been suggested including placement of connective tissue grafts over the extraction sites (Tal 1999), grafting with autogenous bone graft (Becker et al. 1994; Pendarvis & Sandifer 2008) and/or bone substitutes (Ashman 2000) to fill up the defect and utilization of barrier membranes (Cardaropoli & Cardaropoli 2008; Fickl et al. 2008; Iasella et al. 2003; Irinakis & Tabesh 2007; Lekovic et al. 1997, 1998). The maintenance of adequate alveolar bone height and width

or regeneration of alveolar bone is crucial for the implant placement not only for the support of the prosthesis but also for the aesthetic outcome (Misch 1993).

Where alveolar ridges are insufficient for the placement of implants, various localized ridge augmentation surgical procedures have been advocated (Cornelini 2008; Fickl et al. 2008; Geurs et al. 2008; Wang & Tsao 2008). The autogenous soft tissue and bone graft have been proven to provide predictable aesthetic results; however these techniques require a second surgical site for harvesting the donor tissue (Minsk 2004). This may lead to postoperative morbidity and increased the potential discomfort associated with the second surgical site.

An acellular dermal matrix allograft AlloDerm® (Biohorizon, Life Cell Corporation, Branchburg, USA) has been advocated for use as a substitute for autogenous connective tissue graft in many surgical procedures such as in root coverage for gingival recession defect (Minsk 2004), to increase zone of attached gingiva (Schulman 1996), for the management of soft tissue ridge deformities (Batista et al. 2001) and for oronasal fistulae repair (Cole et al. 2006; Kirschner et al. 2006). AlloDerm® is derived from human soft tissue, chemically processed to

remove all epidermal and dermal cells (antigenic cells) while preserving the remaining bioactive dermal matrix. According to the manufacturer, the bioactive matrix which consist of collagen, elastin, blood vessels channels and bioactive proteins have the ability to support natural revascularization, cell repopulation and tissue remodeling (Biohorizons 2005). It has also been suggested that the ultra-structural integrity of the acellular matrix is maintained, thus avoiding an induction of inflammatory response (Batista et al. 2001; Minsk 2004).

The role of bone graft in extraction socket augmentation at the time of tooth extraction is to act as a scaffold and to promote bone ingrowth. Various augmentation techniques with different osseous graft materials have been described (Artzi et al. 2000; Becker et al. 1996, 1998; Buser et al. 1996; Donos et al. 2002; Fowler & Breault 2001; Yukna et al. 2003). Porous bovine hydroxyapatite bone graft which has been tested for its efficacy (Becker et al. 1998; Carmagnola et al. 2003; Froum et al. 1998; Zitzmann et al. 1997) was reported in some studies to be highly osteoconductive with evidence of vital bone formation when used with or without barrier membrane (Artzi et al. 2000; Carmagnola et al. 2003; Froum et al. 1998).

This case report describes the technique for soft tissue and ridge preservation procedure after tooth extraction in the anterior maxilla utilizing acellular dermal graft (AlloDerm®, Biohorizon, Life Cell Corporation, Branchburg, USA) in combination with bovine bone graft particles (Bio-Oss®, Geistlich, Wolhusen, Switzerland). The missing tooth was replaced with implant-supported porcelain-fused to metal crown.

CASE REPORT

A 67-year-old Malay male was referred to the Department of Periodontology, Faculty of Dentistry, University of Malaya for the management of cracked root-treated maxillary right central incisor and other missing teeth with implants. Being a former smoker, he also had generalized chronic periodontitis and recession of the gingiva. During the course of the periodontal treatment, the crown of the maxillary right central incisor was fractured as a result of secondary caries and brittleness of an endodontically treated tooth. The patient was a highly motivated pensioner, former smoker, in good general health.

Extraorally there were no abnormalities detected and he had a low smile line. Intraorally, there was a retained root of the maxillary right central incisor; associated with abscess and gingival inflammation. The periodontal condition was stable with good oral hygiene although most of the teeth exhibited generalized gingival recession.

The orthopantomogram radiograph demonstrated generalized horizontal bone loss involving one third of the root length in both the maxilla and mandible. Intraoral periapical radiograph showed enlargement of periodontal ligament space around the root of the right maxillary central incisor and the presence of a vertical bony defect mesially (Figure 1). Because of the poor prognosis of

the retained root, it was extracted and at the same time an attempt was made to preserve the ridge. The surgical procedure was carried out following full mouth scaling and root planing. The whole procedure was explained to the patient and consent was obtained.

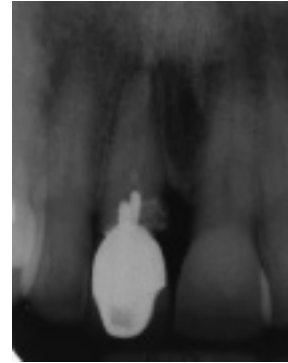

FIGURE 1. Intraoral periapical radiograph of tooth 11 with the crown still intact which was taken during the prosthodontic visit before the referral

PREPARATION OF DONOR TISSUE / ALLODERM REHYDRATION PROCEDURE

The acellular dermal matrix allograft (AlloDerm®) was rehydrated prior to the surgical procedure following the manufacturer's instruction. The tissue was first completely submerged and soaked in normal saline at a temperature of 37°C for approximately 10 min. Once the tissue was rehydrated, the paper backing was removed and the tissue was then soaked in another dish.

SURGICAL PROCEDURE

After local anesthesia was administered, sulcular incision was made from distal of maxillary right canine to distal of left lateral incisor on both labial and palatal sides as in the envelope technique. The partial-thickness flaps were raised beyond the mucogingival junction and loss or resorption of the labial plate of the root was evident. Periosteum was used to extract the maxillary right central incisor root. The granulation tissues in the socket were completely curetted and irrigated using normal saline. Prior to placing the bone substitute, the rectangular AlloDerm® tissue graft with dimensions 1 × 2 cm and 0.89-1.65 mm thickness was trimmed to fit the recipient site. Bone graft which was mixed with blood collected from the surgical site was then packed into the extraction socket until it was completely filled.

AlloDerm® has two distinct surfaces that can be differentiated by placing blood on either side of the tissue. The non-permeable basement membrane side is smooth, whereas the connective tissue side is rough and absorbs blood. The orientation of the allograft has been shown to have no effect on the treatment outcome (Henderson et al. 2001). AlloDerm® was placed with the connective tissue side facing the inner part of the flaps and it completely

covered the labial bony fenestration (Figure 2). The flap was then coronally repositioned and secured with 5/0 Black Silk sutures to cover the soft tissue graft as much as possible (Figure 3). Firm pressure was applied using sterile gauze for a few minutes for the soft tissue graft to adapt and adhere to the recipient bed.

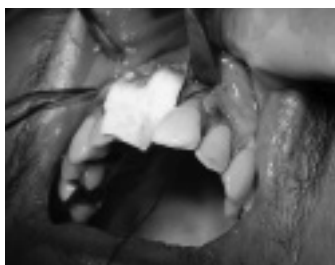

FIGURE 2. Inserting the AlloDerm® tissue graft over the socket with the greater part towards the labial

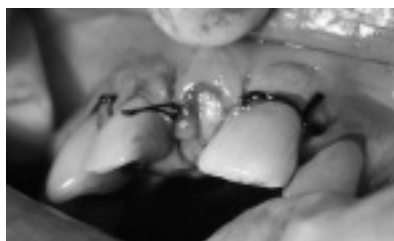

FIGURE 3. The flap was coronally repositioned and sutured

POSTOPERATIVE INSTRUCTIONS

The patient was advised to refrain from brushing in the surgical area for the first 2 weeks after graft placement so as not to disturb the healing. Extra-oral ice application for the first 24 - 48 h was recommended. Antibiotic coverage was prescribed for 7 days and the patient was instructed to use 0.12% chlorhexidine mouthwash daily for the first 3 weeks. Soft diet was recommended for 4 - 7 days. The provisional acrylic denture was relined with tissue conditioner and the occlusion was relieved from the opposing teeth.

POSTOPERATIVE REVIEWS

The patient was reviewed every week for the first month, every 2 weeks for 2 months and monthly until 6 months to evaluate the healing. During the reviews full mouth debridement was performed as well as oral hygiene reinforcement. At one week postoperative review, the superficial surface of AlloDerm® appeared as whitish stiff tissue (Figure 4). The superficial necrotic layer was removed to reveal the underlying healthy healing granulation tissue at second week review.

Six months after the surgery (Figure 5), an intraoral periapical radiograph of the post-surgical area was taken for implant planning. Bone mapping was performed and buccolingual width of edentulous ridge was measured to

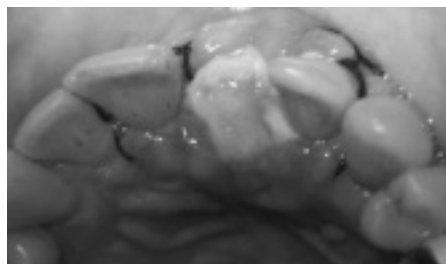


FIGURE 4. Review 1 week postoperatively

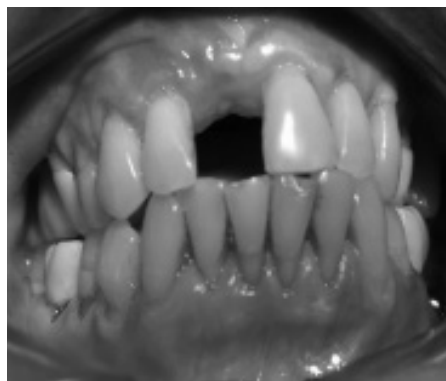

FIGURE 5. Full mouth view after 6 months of the regenerative procedure

be 7 mm. An 11 mm length implant of 3.5 mm diameter (Ankylos®, Friadent, Mannheim, Germany) was surgically placed (Figure 6). The implant was exposed 3 month later and at this second stage surgery, an anatomic healing abutment was placed (Figure 7). Maxillary impression was taken using a polyether impression material (Impregum®, 3M, USA) after the well architecture gingival cuff had formed 3 weeks later. The final restoration was cemented with zinc-oxide eugenol temporary cement (Temp Bond NE®, Kerr, Romulus, USA) and the patient was reviewed after one month (Figure 8). Hence the patient was reviewed 6 monthly for a year and then annually. The appearance at the 4-years review is shown in Figure 9. Reviewed again after 8 years showed stable condition at the implant region and healthy periodontal tissue was maintained. Although the buccal mucosa over the implant was slightly pale pink in colour, there were no bleeding on probing or any periodontal pocket ≥ 3 mm detected surrounding the dental implant (Figure 10). Periapical radiograph at the 8th year shows only slight vertical bone resorption at the mesial aspect of the implant (Figure 11) with clinically no exposure or mobility of the implant noted.

DISCUSSION AND CONCLUSION

In this present case adequate soft tissue buccolabially was available for implant placement 6 months after socket preservation procedure with acellular dermal graft and xenograft bone graft (Bio-Oss®). Although there

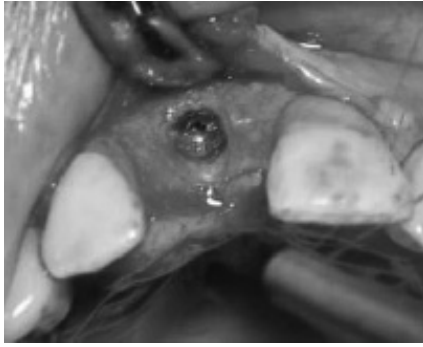


FIGURE 6. Following implant surgery showing the position of implant

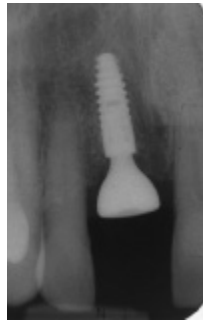

FIGURE 7. Periapical radiograph showing healing abutment in position

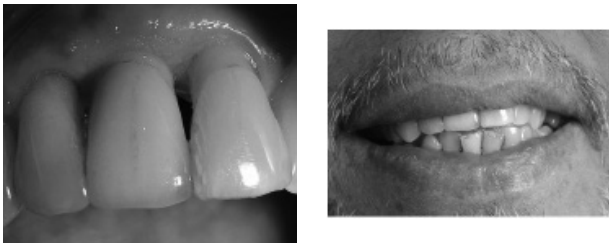


FIGURE 8. Final crown restoration at 4 weeks after cementation (a) Intraoral view and (b) Extraoral-appearance

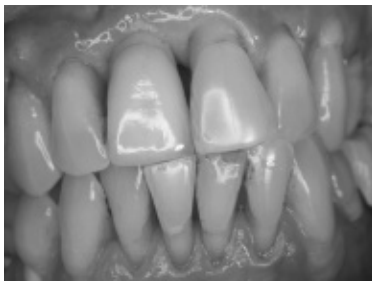

FIGURE 9. The appearance of implant-supported crown after 4 years

were no measurements made at the recipient site prior to the extraction of the maxillary central incisor, bone mapping which was performed 6 months after the socket

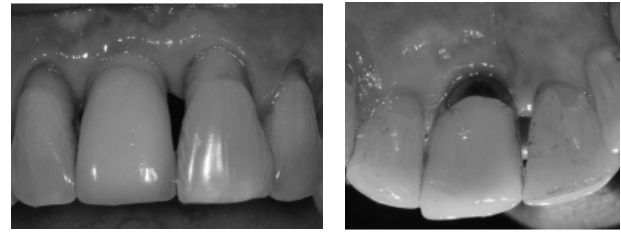


FIGURE 10. The appearance of implant-supported crown at missing 11 after 8 years follow up. (a) Buccal view and (b) Palatal view

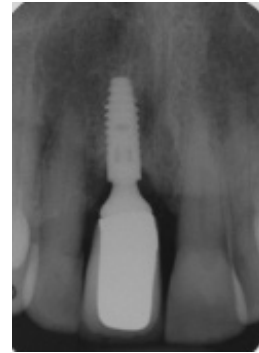

FIGURE 11. Intraoral periapical radiograph of implant replacing tooth 11 during 8 years review

preservation procedure showed 5 mm thickness of the soft tissue buccal and occlusal to the healed extraction socket.

The whitish appearance which was observed a few days post-surgically is a normal presentation during the healing phase of Alloderm® to indicate necrosis of superficial tissues of the graft (Minsk 2004). The revascularization and repopulation of fibroblast and epithelial cells took place from underside of the graft to incorporate the graft into the newly formed tissue (Minsk 2004). Tal et al. (1999) however mentioned that acellular dermal matrix allograft normally takes a longer time to mature compared with autogenous graft where complete healing is achieved at approximately 6 weeks for autogenous graft and about 9 weeks for acellular dermal allograft. The ability of acellular dermal matrix graft to preserve or augment the ridge's soft tissue thickness as compared with the sites that did not receive the grafting materials has also been demonstrated (Luczyszyn et al. 2005).

The use of bovine-derived xenograft in this case is thought to provide structural components similar to that of human bone and with its osteoconductive capability, this served as a scaffold for bone formation (Artzi et al. 2000; Nasr et al. 1999). In addition, bone substitutes also act as space maintainer (Dahlin et al. 1988) and its presence under the soft tissue allograft in maintaining the space allows for potential bone regeneration to occur within the maintained space (Luczyszyn et al. 2005).

There is some scientific evidence to associate the significance of keratinized tissue in influencing long-term survival of implants (Bengazi et al. 1996; Wennström

et al. 1994) and the presence of adequate keratinized tissue as seen in this patient may have enhanced the aesthetic outcome of the therapy. The preservation and/or reconstruction of keratinized mucosa around dental implants is not only to facilitate reconstructive procedures and to improve aesthetics, but equally important to allow plaque control during oral hygiene procedures (Block & Kent 1990; Buser et al. 1990). Minor shrinkage 3-6 months later was also reported (Batista et al. 2001) and hence in this case the socket was slightly overfilled with bone filler. Some graft material could be lost during the healing period post-surgically.

In conclusion, the use of an acellular dermal matrix allograft in combination with bone xenograft in this present case has been shown to facilitate implant placement and produce aesthetically acceptable restorative outcome in the aesthetic zone even in this patient with generalized gingival recession. Clinical studies are suggested to compare this material with other soft tissue grafts for preservation of the alveolar ridge for aesthetic restorative outcomes.

REFERENCES

- Artzi, Z., Tal, H. & Dayan, D. 2000. Porous bovine bone mineral in healing of human extraction sockets. Part 1: Histomorphometric evaluations at 9 months. *Journal of Periodontology* 71: 1015-1023.
- Ashman, A. 2000. Postextraction ridge preservation using a synthetic alloplast. *Implant Dentistry* 9: 168-176.
- Batista, E.L.J., Batista, F.C. & Novaes, A.B. 2001. Management of soft tissue ridge deformities with acellular dermal matrix. Clinical approach and outcome after 6 months of treatment. *Journal of Periodontology* 72: 265-273.
- Bays, R. 1986. The pathophysiology and anatomy of edentulous bone loss. *Reconstructive Preprosthetic Oral and Maxillofacial Surgery* 1: 1-17.
- Becker, W., Clokie, C., Sennerby, L., Urist, M.R. & Becker, B.E. 1998. Histologic findings after implantation and evaluation of different grafting materials and titanium micro screws into extraction sockets: Case reports. *Journal of Periodontology* 69: 414-421.
- Becker, W., Urist, M., Becker, B.E., Jackson, W., Parry, D.A., Bartold, M., Vincenzi, G., De Georges, D. & Niederwanger, M. 1996. Clinical and histologic observations of sites implanted with intraoral autologous bone grafts or allografts. 15 human case reports. *Journal of Periodontology* 67: 1025-1033.
- Becker, W., Becker, B.E. & Caffesse, R. 1994. A comparison of demineralized freeze-dried bone and autologous bone to induce bone formation in human extraction sockets. *Journal of Periodontology* 65: 1128-1133.
- Bengazi, F., Wennstrom, J.L. & Lekholm, U. 1996. Recession of the soft tissue margin at oral implants. A 2-year longitudinal prospective study. *Clinical Oral Implants Research* 7: 303-310.
- Biohorizons. 2005. Alloderm® regenerative tissue matrix. www.biohorizons.com/document/MLD_102.pdf. Accessed in November 2005.
- Block, M.S. & Kent, J.N. 1990. Factors associated with soft- and hard-tissue compromise of endosseous implants. *Journal of Oral Maxillofacial Surgery* 48: 1153-1160.
- Buser, D., Dula, K., Hirt, H.P. & Schenk, R.K. 1996. Lateral ridge augmentation using autografts and barrier membranes: A clinical study with 40 partially edentulous patients. *Journal of Oral Maxillofacial Surgery* 54: 420-432.
- Buser, D., Weber, H.P. & Lang, N.P. 1990. Tissue integration of non-submerged implants. 1-year results of a prospective study with 100 ITI hollow-cylinder and hollow-screw implants. *Clinical Oral Implants Research* 1: 33-40.
- Cardaropoli, D. & Cardaropoli, G. 2008. Preservation of the postextraction alveolar ridge: A clinical and histologic study. *International Journal of Periodontics and Restorative Dentistry* 28: 469-477.
- Carmagnola, D., Adriaens, P. & Berglundh, T. 2003. Healing of human extraction sockets filled with Bio-Oss. *Clinical Oral Implants Research* 14: 137-143.
- Cole, P., Horn, T.W. & Thaller, S. 2006. The use of decellularized dermal grafting (AlloDerm) in persistent oro-nasal fistulas after tertiary cleft palate repair. *Journal of Craniofacial Surgery* 17: 636-641.
- Cornelini, R., Barone, A. & Covani, U. 2008. Connective tissue grafts in postextraction implants with immediate restoration: A prospective controlled clinical study. *Practical Procedures and Aesthetics Dentistry* 20: 337-343.
- Dahlin, C., Linde, A. & Gottlow, J. 1988. Healing of bone defects by guided tissue regeneration. *Plastic Reconstructive Surgery* 81: 672-676.
- Donos, N., Kostopoulos, L. & Karring, T. 2002. Alveolar ridge augmentation using a resorbable copolymer membrane and autogenous bone grafts. An experimental study in the rat. *Clinical Oral Implants Research* 13: 203-213.
- Fickl, S., Zuhr, O., Wachtel, H., Stappert, C.F., Stein, J.M. & Hürzeler, M.B. 2008. Dimensional changes of the alveolar ridge contour after different socket preservation techniques. *Journal of Clinical Periodontology* 35: 906-913.
- Fowler, E.B. & Breault, L.G. 2001. Ridge augmentation with a folded acellular dermal matrix allograft: A case report. *Journal of Contemporary Dental Practice* 2: 32-40.
- Froum, S.J., Weinberg, M.A. & Tarnow, D. 1998. Comparison of bioactive glass synthetic bone graft particles and open debridement in the treatment of human periodontal defects. A clinical study. *Journal of Periodontology* 69: 698-709.
- Geurs, N.C., Korostoff, J.M., Vassilopoulos, P.J., Kang, T.H., Jeffcoat, M., Kellar, R. & Reddy, M.S. 2008. Clinical and histologic assessment of lateral alveolar ridge augmentation using a synthetic long-term bioabsorbable membrane and an allograft. *Journal of Periodontology* 79: 1133-1140.
- Henderson, R.D., Greenwell, H., Drisko, C., Regennitter, F.J., Lamb, J.W., Mehlbauer, M.J., Goldsmith, L.J. & Rebitski, G. 2001. Predictable multiple site root coverage using an acellular dermal matrix allograft. *Journal of Periodontology* 72: 571-582.
- Iasella, J.M., Greenwell, H. & Miller, R.L. 2003. Ridge preservation with freeze-dried bone allograft and a collagen membrane compared to extraction alone for implant site development: A clinical and histologic study in humans. *Journal of Periodontology* 74: 990-999.
- Irinakis, T. & Tabesh, M. 2007. Preserving the socket dimensions with bone grafting in single sites: An esthetic surgical approach when planning delayed implant placement. *Journal of Oral Implantology* 33: 156-163.
- Kirschner, R.E., Cabiling, D.S., Slemper, A.E., Siddiqi, F., LaRossa, D.D. & Losee, J.E. 2006. Repair of oronasal fistulae with acellular dermal matrices. *Plastic Reconstructive Surgery* 118: 1431-1440.

- Lekovic, V., Camargo, P.M., Klokkevold, P.R., Weinlaender, M., Kenney, E.B., Dimitrijevic, B. & Nedic, M. 1998. Preservation of alveolar bone in extraction sockets using bioabsorbable membranes. *Journal of Periodontology* 69: 1044-1049.
- Lekovic, V., Kenney, E.B., Weinlaender, M., Han, T., Klokkevold, P., Nedic, M. & Orsini, M. 1997. A bone regenerative approach to alveolar ridge maintenance following tooth extraction. Report of 10 cases. *Journal of Periodontology* 68: 563-570.
- Lindhe, J., Karring, T. & Lang, K. 2003. *Textbook of Clinical Periodontology and Implant Dentistry* 4th ed. Copenhagen: Blackwell Munksgaard. Chapter 27 and 28.
- Luczynski, S.M., Papalexiou, V., Novaes, A.B. Jr., Grisi, M.F., Souza, S.L. & Taba, M. Jr. 2005. Acellular dermal matrix and hydroxyapatite in prevention of ridge deformities after tooth extraction. *Implant Dentistry* 14: 176-184.
- Mecall, R.A. & Rosenfeld, A.L. 1996. Influence of residual ridge resorption patterns on fixture placement and tooth position. Part 111: Presurgical assessment of ridge augmentation requirements. *International Journal of Periodontics and Restorative Dentistry* 16: 322-337.
- Mecall, R.A. & Rosenfeld, A.L. 1992. The influence of residual ridge resorption patterns on implant fixture placement and tooth position. II. Presurgical determination of prosthesis type and design. *International Journal of Periodontics and Restorative Dentistry* 12: 32-51.
- Mecall, R.A. & Rosenfeld, A.L. 1991. Influence of residual ridge resorption patterns on implant fixture placement and tooth position. *International Journal of Periodontics and Restorative Dentistry* 11: 8-23.
- Minsk, L. 2004. The use of acellular dermal connective tissue graft for root coverage in periodontal plastic surgery. *Compendium* 25: 170-176.
- Misch, C.E. 1993. *Contemporary Implant Dentistry*. St. Louis: CV Mosby-Year Book. pp. 427-431.
- Nasr, H.F., Aichelmann-Reidy, M.E. & Yukna, R.A. 1999. Bone and bone substitutes. *Periodontology* 2000 19: 74-86.
- Pendarvis, W.T. & Sandifer, J.B. 2008. Localized ridge augmentation using a block allograft with subsequent implant placement: A case series. *International Journal of Periodontics and Restorative Dentistry* 28: 509-515.
- Schulman, J. 1996. Clinical evaluation of an acellular dermal allograft for increasing the zone of attached gingiva. *Practical Periodontics and Aesthetics Dentistry* 8: 201-208.
- Tal, H. 1999. Autogenous masticatory mucosal grafts in extraction socket seal procedures: A comparison between sockets grafted with demineralized freeze-dried bone and deproteinized bovine bone mineral. *Clinical Oral Implants Research* 10: 289-296.
- Wang, H.L. & Tsao, Y.P. 2008. Histologic evaluation of socket augmentation with mineralized human allograft. *International Journal of Periodontics and Restorative Dentistry* 28: 231-237.
- Wennström, J.L., Bengazi, F. & Lekholm, U. 1994. The influence of the masticatory mucosa on the peri-implant soft tissue condition. *Clinical Oral Implants Research* 5: 1-8.
- Yukna, R.A., Castellon, P., Saenz-Nasr, A.M., Owens, K., Simmons, J., Thunthy, K.H. & Mayer, E.T. 2003. Evaluation of hard tissue replacement composite graft material as a ridge preservation/augmentation material in conjunction with immediate hydroxyapatite-coated dental implants. *Journal of Periodontology* 74(5): 679-686.
- Zitzmann, N.U., Naef, R. & Schärer, P. 1997. Resorbable versus nonresorbable membranes in combination with Bio-Oss for guided bone regeneration. *International Journal of Oral Maxillofacial Implants* 12: 844-852.

Haslina Taib
Unit of Periodontology, School of Dental Sciences
Universiti Sains Malaysia
16150 Kubang Kerian, Kelantan
Malaysia

Khamiza Zainal Abidin
Ministry of Health, Ipoh, Perak
Malaysia

Tara Bai Taiyeb Ali*
Department of Oral Pathology, Oral Medicine and Periodontology
Faculty of Dentistry, University of Malaya
50603 Kuala Lumpur
Malaysia

Norsiah Yunus
Department of Prosthetic Dentistry, Faculty of Dentistry
University of Malaya
50603 Kuala Lumpur
Malaysia

*Corresponding author; email: tara@um.edu.my

Received: 18 July 2012
Accepted: 19 August 2013